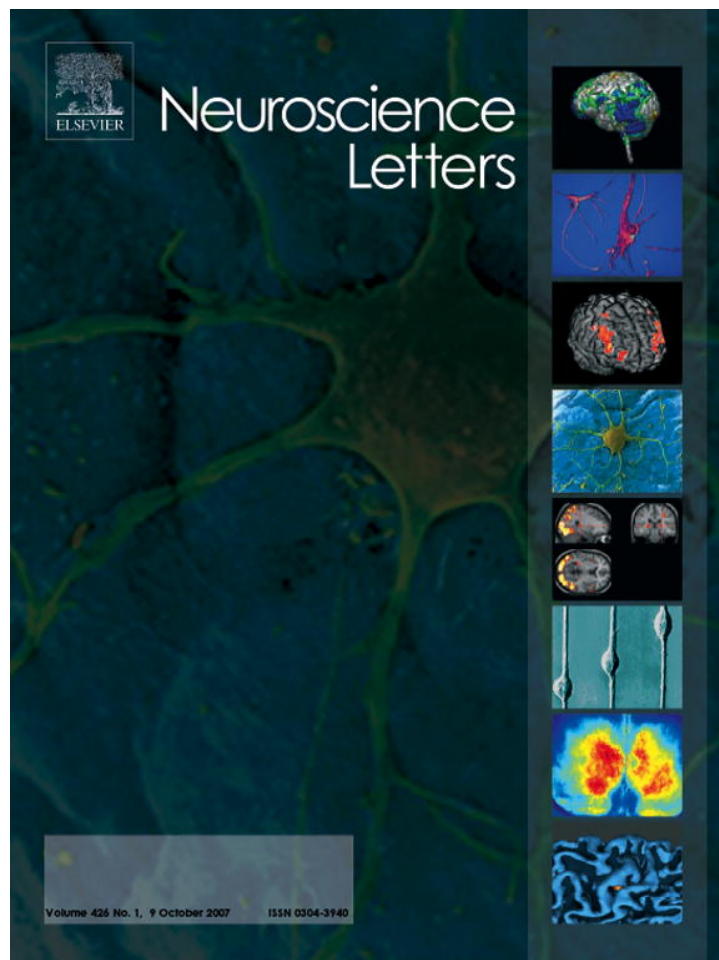



This article was published in an Elsevier journal. The attached copy is furnished to the author for non-commercial research and education use, including for instruction at the author's institution, sharing with colleagues and providing to institution administration.

Other uses, including reproduction and distribution, or selling or licensing copies, or posting to personal, institutional or third party websites are prohibited.

In most cases authors are permitted to post their version of the article (e.g. in Word or Tex form) to their personal website or institutional repository. Authors requiring further information regarding Elsevier's archiving and manuscript policies are encouraged to visit:

<http://www.elsevier.com/copyright>



# High frequency localised “hot spots” in temporal lobes of patients with intractable tinnitus: A quantitative electroencephalographic (QEEG) study

Heather Ashton<sup>a</sup>, Keith Reid<sup>a</sup>, Richard Marsh<sup>a</sup>, Ian Johnson<sup>b</sup>, Kai Alter<sup>a,\*</sup>, Tim Griffiths<sup>a</sup>

<sup>a</sup> School of Neurology, Neurobiology and Psychiatry, University of Newcastle upon Tyne, Newcastle upon Tyne NE2 4HH, United Kingdom

<sup>b</sup> Department of Otolaryngology/Head & Neck Surgery, The Freeman Hospital, High Heaton, Newcastle upon Tyne NE7 7DN, United Kingdom

Received 14 March 2007; received in revised form 26 July 2007; accepted 7 August 2007

## Abstract

Tinnitus, the perception of noise in the absence of an external auditory stimulus, is common, frequently distressing and often intractable. It is associated with a number of conditions including deafness but may arise spontaneously. Brain imaging studies indicate increased neuronal excitability and decreased density of benzodiazepine receptors in temporal (auditory) cortex but the source and mechanism of such changes are unknown. Various electroencephalographic (EEG) abnormalities involving temporal lobe and other brain areas have been described but recordings have been limited to standard EEG wave bands up to frequencies of 22 Hz. This clinical study of otherwise healthy patients with intractable unilateral tinnitus, using quantitative EEG power spectral mapping (QEEG), identified discrete localised unilateral foci of high frequency activity in the gamma range (>40–80 Hz) over the auditory cortex in eight patients experiencing tinnitus during recording. These high frequency “hot spots” were not present in 25 subjects without tinnitus. The results suggest that further EEG investigations should include recordings in the gamma frequency range since such high frequency oscillations are believed to be necessary for perception. Identification of “hot spots” in tinnitus patients would provide a means for monitoring the effects of new treatments. These findings may also provide a model for exploration of more complex phenomena such as verbal and musical hallucinations.

© 2007 Elsevier Ireland Ltd. All rights reserved.

**Keywords:** Tinnitus; Quantitative EEG (QEEG); Temporal lobe high frequency (>40–80 Hz) foci; Auditory hallucinations

Tinnitus is the sensory perception of noise in the absence of an external auditory stimulus. It is common, often intractable and frequently distressing. The perception may vary from a single tone to hissing, whistling, mechanical or more complex sounds. It may be unilateral or bilateral, constant or intermittent. It may arise spontaneously or in association with several states including drug ingestion or withdrawal, and chronic deafness.

The neurological basis of tinnitus is unclear although several theories have been proposed. In the ‘phantom limb’ model, decreased auditory input to the cortex because of deafness may increase local excitability, leading to increased firing of cortical auditory neurones [5] causing hallucinations of sound. Imbalance of inhibition and excitation via gamma aminobutyric acid (GABA) and glutamate influences in mediotemporal cortex [12] or an ‘edge’ phenomenon occurring between two non-synchronous areas of neural firing [9] have also been suggested.

Decreased density of benzodiazepine receptors in the medial temporal cortex in patients with tinnitus has been demonstrated by single proton emission computed tomography (SPECT) and proposed as a precipitant or correlate of tinnitus [4,15].

All these proposals imply localised increased neural activity in auditory cortical areas as a basis for tinnitus. Quantitative EEG power spectral mapping (QEEG) is a simple and relatively inexpensive method for measuring regional brain activity and various EEG abnormalities in temporal lobe and other areas have been described in tinnitus patients [13,14,19,20]. The findings have been confusing, showing both increase and decrease in average power, with opposite effects and different cortical distributions in males and females. However, the recordings have been confined to frequencies only up to 22 Hz. Yet in man depth electrocortical EEG recordings indicate that auditory perception induces gamma activity at >40–100 Hz [2,3], and such high frequency gamma oscillations may be neural correlates of perception and consciousness [7,16,18,22].

We hypothesised that, using QEEG, we would be able to detect localised high frequency (>40 Hz) activity over auditory cortical areas in subjects with tinnitus. Such discrete high

\* Corresponding author at: Newcastle University Medical School, Framlington Place, Newcastle upon Tyne NE2 4HH, UK. Fax: +44 191 222 5227.

E-mail address: [kai.alter@ncl.ac.uk](mailto:kai.alter@ncl.ac.uk) (K. Alter).

frequency EEG foci have not been reported in this condition. Secondly, if such foci were present, the technique would provide a means for testing and monitoring the effects of various treatments for tinnitus. A third hypothesis was that tinnitus, by definition an hallucination or phantom, might serve as a simple model for investigating complex hallucinations that also reach consciousness, and might show a similar pattern. Fourth, it was anticipated that the results would shed light on an important correlate of abnormal neuronal activity in tinnitus. To explore these possibilities, we undertook a preliminary investigation of patients with intractable unilateral tinnitus, recording regional cortical activity at frequencies up to ~80 Hz.

The tinnitus subjects were eight otherwise healthy patients referred from the local Ear, Nose and Throat (ENT) clinic for further investigation because of intractable tinnitus which had been present for 2–44 years (Table 1). All were right handed and had predominantly unilateral, left or right tinnitus. Structural brain imaging results (computerised tomography (CT) and magnetic resonance imaging (MRI)) were normal and none were taking centrally acting medications. On audiometry, six of the eight subjects showed some degree of high frequency sensorineural deafness in one or both ears and had a past history of ear infections but none had other known causes of tinnitus. The perceived character of the tinnitus varied between patients and included single high tone, low drumming, hissing, whistling, siren-like and banging or clicking noises. The results were compared with 25 normal subjects without tinnitus. These subjects had not had audiometry, CT or MRI scans but were recorded with the same technique and under similar conditions.

In four of the patients and 21 of the tinnitus-free subjects EEG was recorded from 18 small silver/silver chloride disposable surface electrodes with impedance below 3 K $\Omega$  located at F<sub>7</sub>, F<sub>3</sub>, F<sub>z</sub>, F<sub>4</sub>, F<sub>8</sub>, C<sub>3</sub>, C<sub>z</sub>, C<sub>4</sub>, T<sub>7</sub>, T<sub>8</sub>, TP<sub>7</sub>, TP<sub>8</sub>, P<sub>3</sub>, P<sub>z</sub>, P<sub>4</sub>, O<sub>1</sub>, O<sub>2</sub>, N<sub>z</sub>, all referred to linked mastoids. The EEG signals were amplified using a Neuroscan Synamps system (Neurosoft Inc., Sterling, VA, USA) and processed using SCAN 4.3 software. Analogue to digital (A/D) conversion rate was 500 Hz. In a further four patients and four tinnitus-free subjects, as new equipment became available, recordings were made from 30 scalp electrode sites using 32 Channel Quick-Cap electrode layout with SINTERED silver chloride electrodes (Med-Tech Systems Ltd., West Sussex, UK). The results were processed using Synamps 2 and SCAN 4.3 software. Impedances were within acceptable system limits; A/D conversion rate was 1000 Hz. Band pass fil-

ters for all subjects were 0.1 Hz high pass, 100 Hz low pass with a 50 Hz notch filter. Brainmaps were constructed using the Neuroscan local (18 scalp electrodes) or global (30 scalp electrodes) interpolation methods (Neuroscan 2003, Document 2203, Revision D). The local interpolation method uses the 1–4 nearest electrodes by applying reciprocal distance weighting in the calculation of brainmaps. The global interpolation method uses all electrodes to calculate values at any given point [17]. The influence of any electrode is affected by weighting functions.

The global interpolation function  $g(x, y)$  is

$$g(x, y) = \mathbf{w}(x, y)^T \mathbf{W}^{-1} \mathbf{v}$$

where  $g(x, y)$  is the globally interpolated value at map coordinates  $x$  and  $y$ . The column vector  $\mathbf{w}(x, y)$  represents the inverse distance squared weights of the map coordinates with respect to electrode locations;  $\mathbf{W}$  is a symmetric matrix of inter-electrode inverse distance squared weights; and  $\mathbf{v}$  is a column vector of the actual potential measurements across all channels. The “T” superscript denotes the transpose operation by which a column vector of dimension  $n(\mathbf{v})$  multiplied by a square matrix of dimension  $n - by - n(\mathbf{W}^{-1})$  multiplied by a row vector of dimension  $n(\mathbf{w}(x, y)^T)$  yields a globally interpolated scalar potential value ( $g(x, y)$ ).

The  $i$ th component of the weights vector  $\mathbf{w}(x, y)$  is given by

$$w_i(x, y) = ((x - x_i)^2 + (y - y_i)^2 + a)^{-1}$$

where  $x_i$  and  $y_i$  are coordinates of the  $i$ th electrode, and  $a$  is a positive constant added to avoid singularity in the expression when  $x = x_i$  and  $y = y_i$ . In this implementation,  $a$  is set to the average inter-electrode distance.

Each element of the symmetric matrix  $\mathbf{W}$  is computed as

$$W_{ij} = ((x_i - x_j)^2 + (y_i - y_j)^2 + a)^{-1}$$

where  $i$  and  $j$  index electrodes (Neuroscan 2003, Document 2203, Revision D).

The subjects were seated in an isolated sound-proofed room connected with a recording room via a one-way glass window and an intercom system. Hearing aids, if used, were removed. Eye movements were minimised by asking the subjects to fixate on a cross marked on a screen placed one metre in front of them and eye movement compensation was derived from nasion (N<sub>z</sub>)/linked mastoid electrodes or VEOG (N<sub>z</sub> = positive; linked infra = negative). The records were visually inspected and any

Table 1  
Summary of patient characteristics and EEG findings

Patient	Sex (M, F)	Age (years)	Deafness	Tinnitus (side/type)	High frequency EEG focus (ipsilateral/contralateral to side of tinnitus)	
1	M	62	R > L	R hissing	R	Ipsilateral
2	M	67	None	L clicking	R	Contralateral
3	M	71	L	L hissing + rattle	R	Contralateral
4	F	41	None	L high tone	L	Ipsilateral
5	F	68	L	L buzz	R	Contralateral
6	M	57	L > R	L buzz	L	Ipsilateral
7	F	53	L	L drumming	L	Ipsilateral
8	M	33	L > R	L buzz	L	Ipsilateral

section still contaminated with eye movement or other artefacts was excluded from analysis. The EEG was recorded continuously for 3 min each with eyes open and eyes closed. Sixty to ninety 2 s artefact-free epochs were subjected to Fast Fourier analysis at each electrode site and averaged in each condition and over a frequency range of 1–80 Hz and plotted using SCAN 4.3.

In all eight patients who experienced tinnitus during EEG recording, the QEEG map showed a unilateral, left or right, localised focus of high frequency activity over the temporal lobe auditory cortex. The average frequency of the focus was greater than 30 Hz, extending to over 80 Hz and maximal at around 60 Hz. Examples of such localised activity in two patients are shown in Figs. 1 and 2, and the results for all patients in Table 1. Activity in the standard EEG bands (delta 0.5–3.9 Hz, theta 4.0–7.9 Hz, alpha 8.0–14.0 Hz, beta 1 and beta 2 14.1–35 Hz) was normal in amplitude, power, and distribution in all patients with no evidence of localised increased power/frequency except occasionally in the beta 2 range. The average power in the localised high frequency areas was between 0.5 and 2  $\mu\text{V}^2/\text{Hz}$ . The high frequency focus was ipsilateral to the perceived tinnitus in five patients but contralateral in three. Foci were present in both the eyes closed and eyes open conditions in most subjects

but were more prominent with eyes open in some. In the tinnitus-free subjects there was no evidence of any high frequency focus.

These results show that all subjects with tinnitus showed a unilateral localised area of high frequency (30–80 Hz, maximum  $\sim 60$  Hz) activity over the temporal lobe auditory cortex. The picture was similar despite individual disparities in the described nature of the tinnitus, presence or degree of deafness, age or sex, and was not present in tinnitus-free subjects. Such “hot spots” of high frequency localised temporal lobe foci have not been described previously in patients with tinnitus.

These new observations open the way to further research into tinnitus and to auditory (and other) hallucinations in general. They appear to confirm our initial hypotheses that localised areas of increased high frequency activity over auditory cortical areas would be found in patients with tinnitus and that such foci might be of use in testing and monitoring treatments for this often intractable condition. They also suggest that tinnitus may be a model for complex verbal or musical auditory hallucinations which sometimes merge with tinnitus. In addition, they identify at least a cortical correlate of tinnitus, although finding the source of the increased cortical activity may require further investigation, since EEG measurements cannot reflect activity

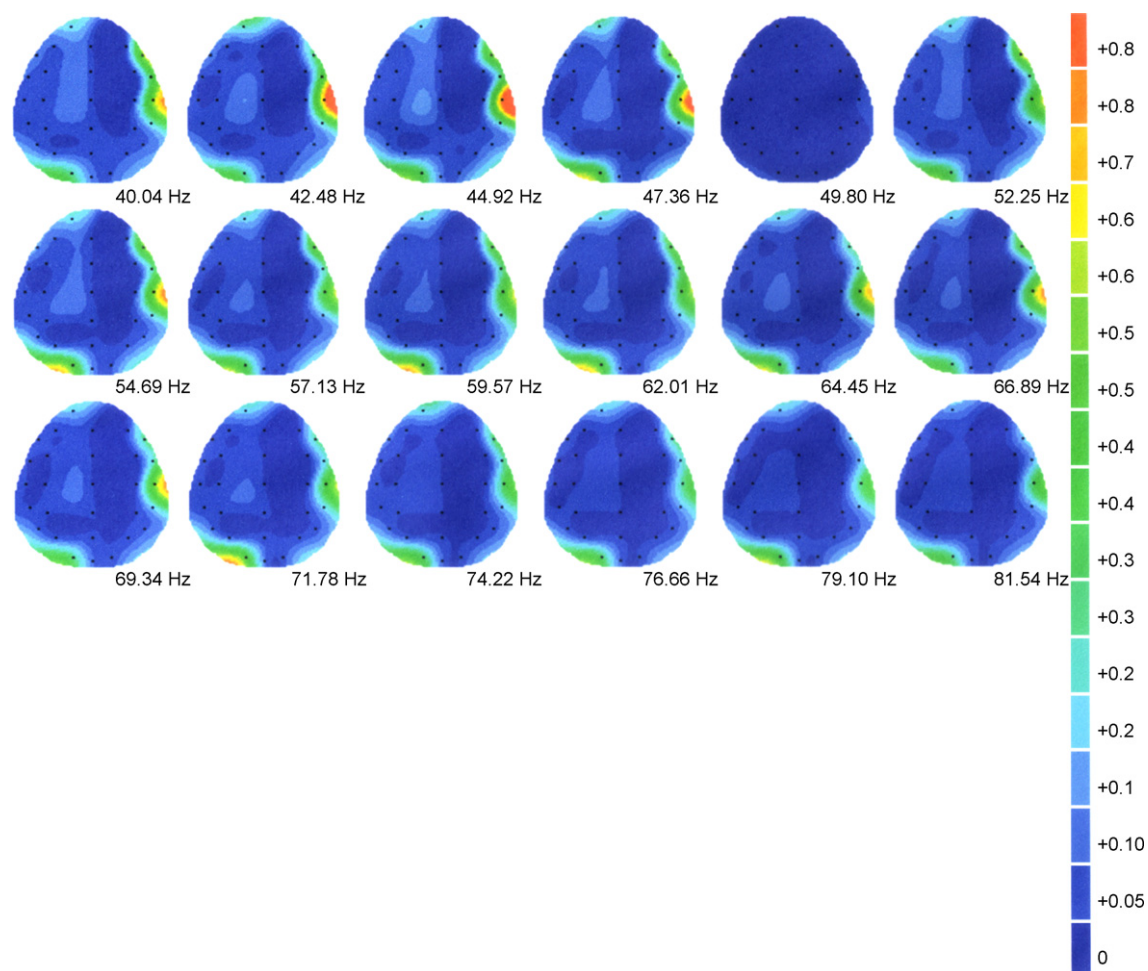


Fig. 1. Brain map of patient with left sided tinnitus showing right sided (contralateral) high frequency temporal lobe focus plotted at approximately 2.4 Hz intervals. Scale shows power ( $\mu\text{V}^2/\text{Hz}$ ).



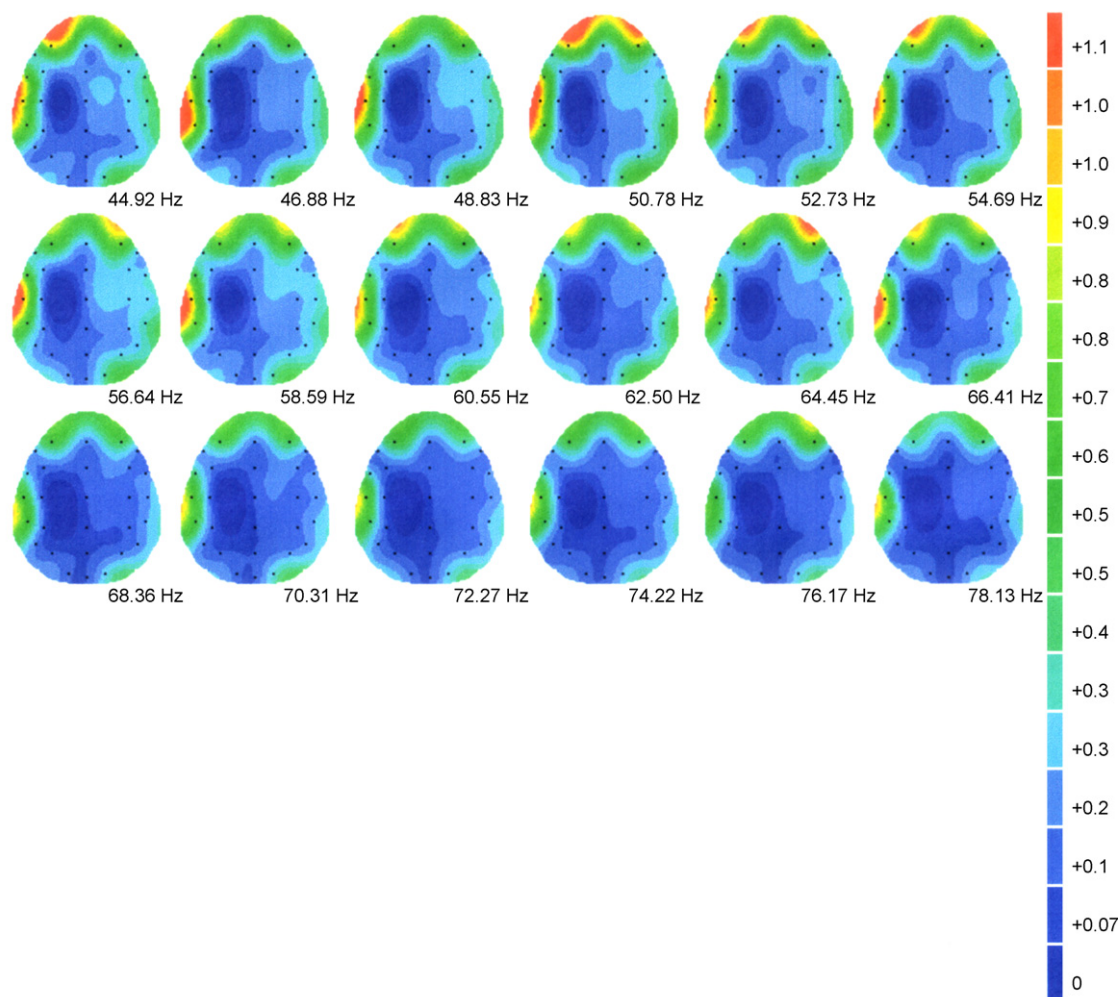


Fig. 2. Brain map of patient with left sided tinnitus showing left sided (ipsilateral) high frequency temporal lobe focus plotted at approximately 2 Hz intervals (frontal activity probably due to muscle activity). Scale shows power ( $\mu\text{V}^2/\text{Hz}$ ).

in subcortical sources. It is likely that magnetoencephalography (MEG) would reveal activity in subcortical brain areas that are responsible for the observed cortical hyperactivity. Furthermore, the spatial resolution of EEG recordings is limited and to define the exact areas of auditory cortex involved, whether primary and/or association areas, would require further study using a larger array of scalp electrodes or with MEG and possibly electrocortical EEG recording.

Although our results are consistent with the various theories of tinnitus outlined in the introduction, they do not define the underlying mechanisms. However, they raise intriguing further questions. One of these is the question of laterality. In five of our patients the focus of fast temporal lobe activity was ipsilateral to the perceived tinnitus, while in three it was contralateral. Our results give no explanation for these differences: there were no clear clinical differences between subjects with ipsilateral or contralateral “hot spots”. Since the projection pathways from the cochlear nerve to the auditory cortex are predominantly crossed, the focus of increased activity might be expected to be on the opposite side to the perceived tinnitus. However, the decussation is incomplete and the extent may vary between individuals and with ageing [23]. The location of the fast activity focus

may also vary with the source of the tinnitus: if the source is external to the cochlear nerve, the focus would be expected to be contralateral, but if the generator was in the auditory cortex itself the tinnitus might be perceived on the same side. It may be of note that tinnitus often persists even when input from the ear is removed by section of the auditory nerve [5]. Also, some cases of tinnitus may be due to more than one coexisting abnormality and the perception of the site of tinnitus may be false or arbitrary. Asymmetries of activation in the inferior colliculus have been noted during acoustic stimulation in a functional magnetic resonance imaging (fMRI) study [10]. Four right handed subjects with normal hearing and unilateral right sided tinnitus showed increased activation on the right side (ipsilateral to the tinnitus) on binaural and left sided acoustic stimulation but increased activation on the left (contralateral) side on right aural stimulation.

Another perplexing finding was that audiograms showed that two subjects had similar degrees of deafness in both ears or normal hearing but the perceived tinnitus and the focus of activity was unilateral. This observation raises the question of hemispheric dominance; is one auditory cortex more specialised for perceiving or interpreting sounds than the other? We have been

able to find no clues in the tinnitus literature concerning laterality and EEG activity; most studies have consisted of subjects with severe bilateral tinnitus. However, it has been suggested in an MEG study [22] that dominance of ~55 Hz activity in the right or left hemisphere determines the laterality of tinnitus perception.

The question of cerebral dominance also raises the question of how tinnitus merges with complex auditory hallucinations. A large number of brain imaging studies, comprehensively reviewed by Weiss and Hecker [21], show that, like tinnitus, verbal hallucinations are associated with sensory modality-specific activation of brain areas involved in normal sensory processing. Thus SPECT imaging measurements in patients experiencing verbal hallucinations have shown increased activity in left superior temporal lobe and Broca's area, regions corresponding to primary and secondary auditory cortex and language centres. Investigations using functional magnetic resonance imaging (fMRI) have given similar results. One study [1], using positron emission tomography (PET) reported decreased activity in both posterior superior temporal lobes, right Broca's homologue and right primary auditory cortex. These results appear somewhat complex and mixed but the patients included subjects with schizophrenia and alcoholism and those taking neuroleptic drugs. Furthermore, verbal hallucinations presumably require processing in a larger number of brain areas than does tinnitus, and are rarely experienced unilaterally.

Descriptions of musical hallucinations have mostly been limited to single case studies. EEG abnormalities in temporal lobe regions have been described [6,11]. The results from one psychiatrically normal right handed patient with normal hearing and normal CT and MRI findings were reported by Kasai et al. [8]. SPECT studies in this patient showed increased cerebral blood flow in right superior and inferior temporal gyri when hallucinations were present but not in their absence. MEG showed increased activity in right auditory association cortex during hallucinations but not when they were absent. The authors note that, while verbal stimuli activate predominantly left sided auditory association areas, non-verbal (musical) stimuli activate the same region with right sided predominance. Thus the right auditory cortex appears to be a focus for musical hallucinations. Such hallucinations are clearly more complex than tinnitus which, from our study, seems capable of activating both left temporal (as in verbal hallucinations) or right temporal (as in musical hallucinations) brain areas.

In conclusion, this small study reports our findings, using QEEG brain mapping, that localised foci of high frequency activity in the gamma range (>40–80 Hz) over temporal cortex areas may be found in patients with central tinnitus. This study indicates that future EEG investigations of tinnitus, which have so far been confined to recording activity at lower frequencies (up to 22 Hz) in the standard delta to beta wave bands, should now include regional recording of high frequency activity over the gamma range which is believed to be necessary for perception and consciousness. It suggests that the technique could be extended to include investigation of verbal and musical hallucinations

and also to visual hallucinations, in which similar foci may perhaps be found in occipital visual areas. EEG recordings have the advantage of simplicity, cause little inconvenience to subjects, and are much cheaper than MEG or fMRI techniques (fMRI has the added disadvantage of producing noise during recording, which may be inappropriate for patients with tinnitus). However, this investigation suggests further studies using MEG may be indicated to elucidate deeper sources of tinnitogenesis. Future EEG research in this laboratory, using a larger sample of tinnitus patients and controls, is planned to include recording of evoked responses to auditory stimuli and continuous noise and coherence mapping. We believe that the present study adds to the potential for testing the effects of new treatments for tinnitus, since present treatments are often inadequate, and may eventually help to elucidate the sites and sources of tinnitogenesis.

## References

- [1] J.M. Cleghorn, S. Franco, B. Szechtman, R.D. Kaplan, H. Szechtman, G.M. Brown, C. Nahmias, E.S. Garnett, Toward a brain map of auditory hallucinations, *Am. J. Psychiatry* 149 (1992) 1062–1069.
- [2] N.E. Crone, D. Boatman, B. Gordon, L. Hao, Induced electrocorticographic gamma activity during auditory perception, *Clin. Neurophysiol.* 112 (2001) 565–582.
- [3] N.E. Crone, A. Sinai, A. Korzeniewska, High-frequency gamma oscillations and human brain mapping with electroencephalography, *Prog. Brain Res.* 159 (2006) 275–295, Chap. 19.
- [4] A. Daftary, A. Shulman, A.M. Strashun, C. Gottschalk, S.S. Zoghbi, J.P. Seibyl, Benzodiazepine receptor distribution in severe intractable tinnitus, *Int. Tinnitus J.* 10 (2004) 17–23.
- [5] J.J. Eggermont, L.E. Roberts, The neuroscience of tinnitus, *Trends Neurosci.* 27 (2004) 676–682.
- [6] G.W. Fenton, D.A. McRae, Musical hallucinations in deaf elderly women, *Br. J. Psychiatry* 155 (1989) 401–403.
- [7] C.M. Gray, Of visual feature integration: still alive and well, *Neuron* 24 (1999) 31–47.
- [8] K. Kasai, T. Asada, M. Yumoto, J. Takeya, H. Matsuda, Evidence for functional abnormality in the right auditory cortex during musical hallucinations, *Lancet* 354 (1999) 1703–1704.
- [9] R. Llinas, F.J. Urbano, F. Leznik, R.R. Ramirez, H.J. van Marle, Rhythmic and dysrhythmic thalamocortical dynamics: GABA systems and the edge effect, *Trends Neurosci.* 28 (2005) 325–333.
- [10] J.R. Melcher, I.S. Sigalovsky, J.J. Guinan Jr., R.A. Levine, Lateralized tinnitus studied with functional magnetic resonance imaging: abnormal inferior colliculus activation, *J. Neurophysiol.* 83 (2000) 1058–1072.
- [11] T.C. Miller, T.W. Crosby, Musical hallucinations in deaf elderly patients, *Ann. Neurol.* 5 (1979) 301–302.
- [12] A. Shulman, Tinnitus neural substrates: an addendum, *Int. Tinnitus J.* 11 (2005) 1–3.
- [13] A. Shulman, M.J. Avitable, B. Goldstein, Quantitative electroencephalography power analysis in subjective idiopathic tinnitus patients: A clinical paradigm shift in the understanding of tinnitus, an electrophysiological correlate, *Int. Tinnitus J.* 12 (2006) 121–132.
- [14] A. Shulman, B. Goldstein, Quantitative encephalography: preliminary report – tinnitus, *Int. Tinnitus J.* 8 (2002) 77–86.
- [15] A. Shulman, A.M. Strashun, B. Goldstein, GABA-benzodiazepine-chloride receptor-targeted therapy for tinnitus control: preliminary report, *Int. Tinnitus J.* 8 (2002) 30–36.
- [16] W. Singer, Neuronal synchrony: a versatile code for the definition of relations? *Neuron* 24 (1999) 49–65.
- [17] A.C.K. Soong, J.C. Lind, G.R. Shaw, Z.J. Koles, Systematic comparisons of interpolation techniques in topographic brain mapping, *Electroenceph. Clin. Neurophysiol.* 87 (1993) 185–195.

- [18] C. Tallon-Baudrey, O. Bertrand, Oscillatory gamma activity in humans and its role in object representation, *Trends Cogn. Sci.* 3 (1999) 151–161.
- [19] E.W. Weiler, K. Brill, Quantitative encephalography patterns in patients suffering from tinnitus, *Int. Tinnitus J.* 10 (2004) 127–131.
- [20] E.W. Weiler, K. Brill, K.A. Tachiki, Quantitative encephalography and tinnitus: a case study, *Int. Tinnitus J.* 6 (2000) 124–126.
- [21] A.P. Weiss, S. Hecker, Neuroimaging of hallucinations: a review of the literature, *Psychiatry Res.* 92 (1999) 61–74.
- [22] N. Weisz, S. Muller, W. Schlee, K. Dohrmann, T. Hartmann, T. Elbert, The neural code of auditory phantom perception, *J. Neurosci.* 7 (2007) 1479–1484.
- [23] T. Yamada, A. Nakamura, K. Horibe, Y. Washimi, M. Bundo, T. Kato, K. Ito, T. Kachi, G. Sobue, Asymmetrical enhancement of middle-latency auditory evoked fields with aging, *Neurosci. Lett.* 337 (2003) 21–24.